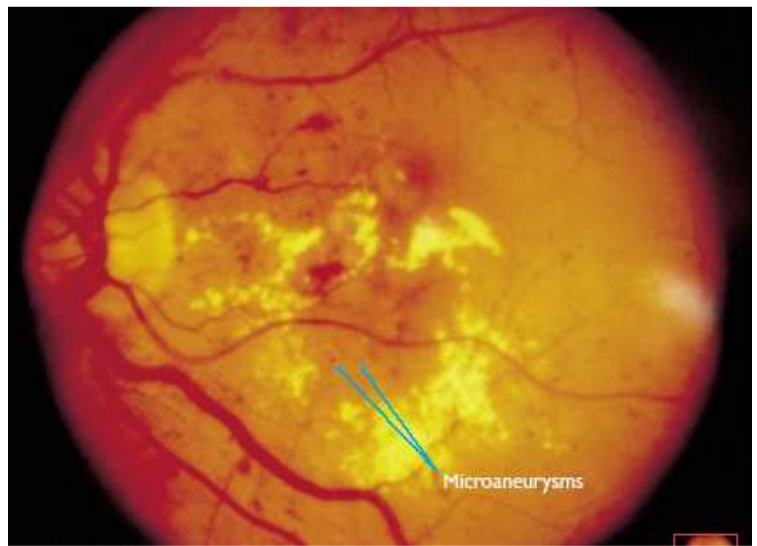


1

Diabetic Retinopathy

- Epidemiology
 - * 1000 registered blind each year
 - * 2% diabetics registered as blind (8% of all Blind Registrations)
 - * 42% with Mild Background DR will progress over 4 yrs
 - * 65% with severe background DR will progress over 4 yrs with 14% developing NV. IRMA & Blot haemorrhages best indicators.
- Importance of good Diabetic Control
 - * Diabetes Control and Complications trial (DCCT) “The effect of intensive treatment of diabetes on the development and progression of long-term complications in insulin-dependent diabetes mellitus” N Engl J Med 1993;977-86
 - ◇ 10 yr prospective study, 1441 type I diabetics age 27yrs randomly allocated to normal insulin regime or intensive treatment with tight control
 - ◇ Diabetic Retinopathy reduced by 76%
 - ◇ Diabetic nephropathy reduced by 35-65%
 - ◇ Diabetic neuropathy reduced by 60%
 - * Once DR is established improving/tight diabetic control initially worsens DR, but after 18 months of treatment with tight diabetic control these patients have less progression of DR.
 - * Hypertension, Diabetic Nephropathy, Pregnancy aggravate DR
- Lisinopril
 - * The effects of Lisinopril of Retinopathy in people with IDDM. Diabetologica (1997) 40: (Suppl 1) I-V
 - ◇ EUCLID Study group 2 yr randomised controlled trial of Lisinopril & Placebo.
 - ◇ Reduced risk of progression of DR by at least one stage by 50%
 - ◇ Reduced risk of progression of DR by 2+ stages by 27%
 - ◇ Reduced risk of progression to Proliferative disease by 18%
 - ◇ Reduced risk of DR forming in people with no DR by 30%
 - ◇ UK licence for treatment of DR in IDDM due next month
- Classification
 - * Background Diabetic Retinopathy
 - * Maculopathy - Macular Oedema
 - ◇ Focal
 - ◇ Diffuse
 - ◇ Ischemic
 - ◇ Mixed
 - * Pre-Proliferative DR

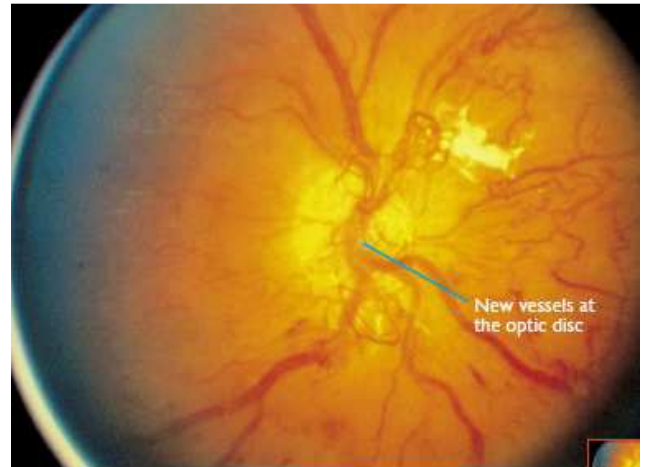
- ◇
- ◇



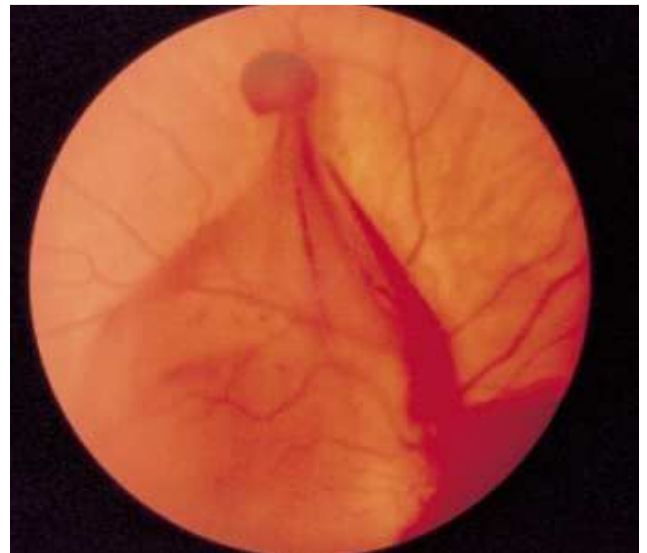
Cotton wool spots

- ◇ Venous abnormalities - Tortuosity, beading, Venous reduplication)
- ◇ Arteriolar abnormalities
- ◇ Intra-retinal micro vascular abnormalities (IRMA)
- * Proliferative Diabetic Retinopathy
 - ◇ New Vessels Elsewhere (NVE)
 - ◇ New Vessels on the Disc (NVE)
- * Advanced Diabetic eye disease
 - ◇ Preretinal haemorrhage/ Vitreous haemorrhage
 - ◇ Rubeosis Iridis
 - ◇ Retinal detachment
 - ◇ Cataract
- **Screening for Diabetic Retinopathy now NSF requirement**
 - ◇ **Target 4/2006 for 80% to be screened, 2006 100%**
 - ◇ **Huge drive to achieve this.**
 - ◇ Early detection is crucial
 - ◇ GP/hospital Doctor - Fundoscopy with dilated pupil – NOT NSF acceptable unless by Ophthalmologist with Stereo Volk Lens
 - ◇ Optometric Screening – Not allowed any more unless supported by Digital camera with proper QA at reading centres
 - ◇ Non-mydriatic Polaroid/35mm/Digital cameras – ONLY digital photographs acceptable. Many placed in diabetic clinics or eye departments, also mobile cameras etc.
 - ◇ Annual for those with no DR, 6mthly for those with any form of DR.
- Management
 - ◇ Observe/record with Photography Digital
 - ◇ Regular review according to severity
 - ◇ Liaise with Lead physician in charge of Diabetic care
- Treatment
 - * Maculopathy
 - ◇ Focal - Focal laser, if no improvement - FFA
 - ◇ Diffuse - FFA - Rx BP/Renal function -
VA>6/60 Rx Grid or modified grid laser - Re-Rx as needed.
If VA <6/60 No Laser
 - ◇ Ischemic - No Rx as laser will worsen ischaemia
 - ◇ Mixed - FFA - Rx areas of leakage, avoid ischemic areas

- ◇ For Diffuse diabetic macular odema unresponsive to laser consider Anti-VEGF intra-vitreous injections into the eye eg Avastin, Mavien or Lucentis. Early trials very promising.
- ◇ Steroid injections largely being replaced by Anti-VEGF injections due to the side effects of cataract and Glaucoma.
- * Proliferative Disease
 - ◇ Mild NVE
 - NIDDM - Rx around NVE, if persist - Full PRP
 - IDDM - mild Scatter PRP
 - ◇ Moderate NVE - mild Scatter PRP
 - ◇ Severe NVE - Full Scatter PRP
 - ◇ NVE/NVE & Fibrosis - Consider Vitrectomy if fibrosis around fovea.



- * Pre-Retinal haemorrhages
 - ◇ Look for NVE - FFA & Laser
 - ◇ Boat shaped - Consider Nd:YAG Opening of internal limiting membrane
- * Vitreous haemorrhage



- ◇ Mild - If view PRP
- ◇ No view - Ultrasound to exclude RD
 - Review 2 - 4 months
 - If clears PRP
 - If Not Vitrectomy and endolaser
- ◇ Severe Ultrasound detached retina – vitrectomy
- ◇ Consider Anti-VEGF treatment

- Cataract
 - * 20% of UK cataracts extractions are on Diabetic patients
 - * Benefit from small incision Phakoemulsification with less post op uveitis or worsening of diabetic retinopathy.
 - * Watch careful post operatively for:
 - ◇ Uveitis, Post Synaechae - damage view for laser later
 - * advancement of DR is common.

The National Screening Programme for Diabetic retinopathy has been going now for 5 years.
www.retinalscreening.nhs.uk for more information.

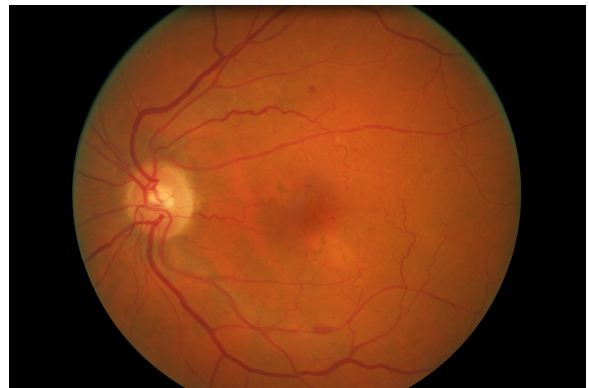New terms which are designed so that computers can handle the grading have now become established in the terminology that is used.

Appendix 1: NSC Retinopathy Grading Standard

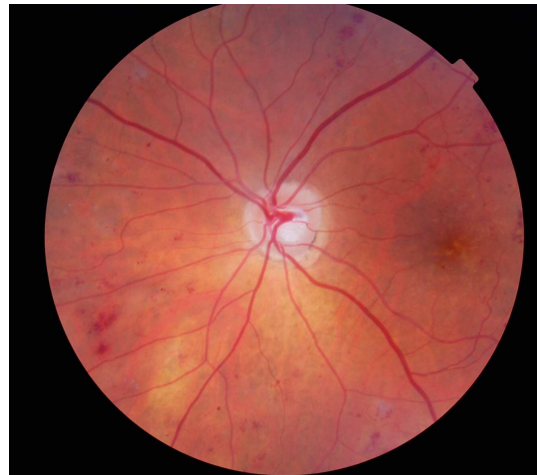Retinopathy (R)

R0 Level 0 None

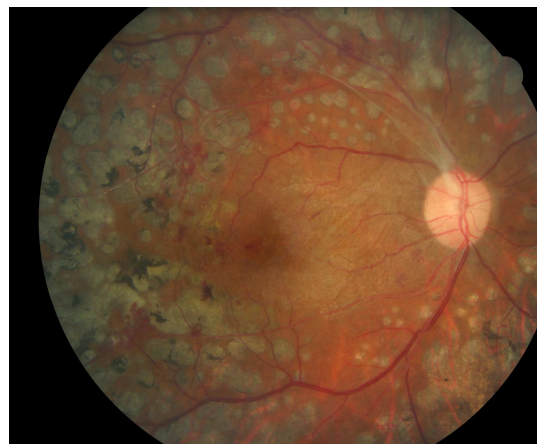
R1 Level 1 Background microaneurysm(s) retinal haemorrhage(s) ± any exudate not within the definition of maculopathy



R2 Level 2 Pre-proliferative venous beading venous loop or reduplication intraretinal microvascular abnormality (IRMA) multiple deep, round or blot haemorrhages (CWS - careful search for above features)



R3 Level 3 Proliferative new vessels on disc (NVD) new vessels elsewhere (NVE) pre-retinal or vitreous haemorrhage pre-retinal fibrosis ± tractional retinal detachment

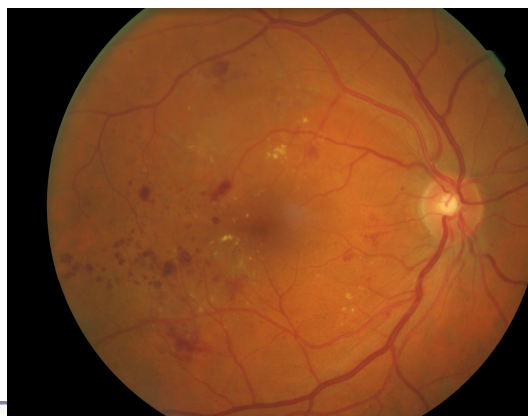

M1 Maculopathy (M)

exudate within 1 disc diameter (DD) of the centre of the fovea circinate or group of exudates within the macula

retinal thickening within 1DD of the centre of the fovea (if stereo available)

any microaneurysm or haemorrhage within 1DD of the centre of the fovea only if associated with a best VA of $\leq 6/12$ (if no stereo)



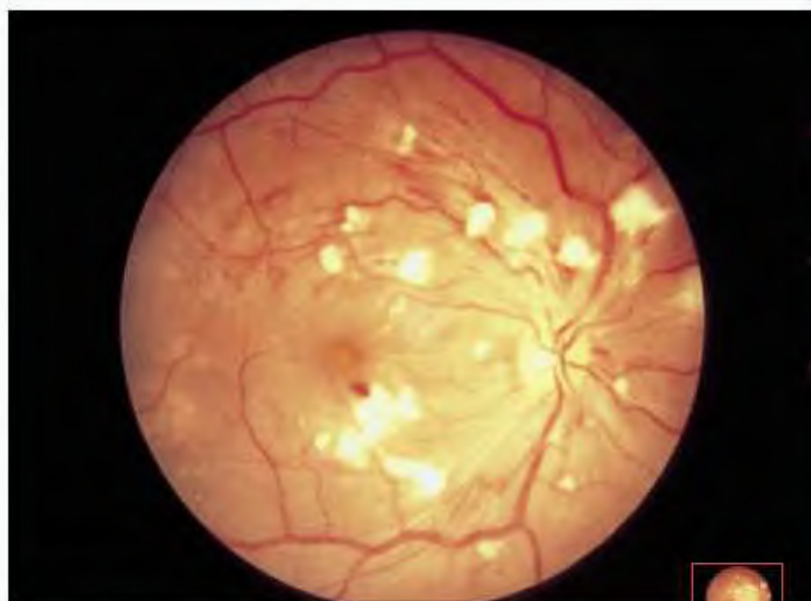Photocoagulation (P) evidence of focal/grid laser to macula evidence of peripheral scatter laser

Unclassifiable (U) Unobtainable / ungradable

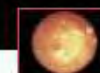Landmark Studies in Diabetes: N Lee 1999

1. The Diabetic Retinopathy Study
2. The Early Treatment Diabetic Retinopathy Study
3. The Diabetic Retinopathy Vitrectomy Study
4. The Diabetes Control and Complications Trial
5. The UKPDS Prospective Diabetes Study Trial.

11.10 Hypertensive Retinopathy



Cotton wool spots, haemorrhages and swollen retina at macula



Actual size

A spectrum of retinal changes occur in hypertension reflecting the severity and duration of disease. Features include vessel changes such as attenuation and arterio-venous nicking, haemorrhage, cotton wool spots and lipid exudate. If the optic disc is swollen, malignant hypertension should be suspected and treated as a medical emergency. Much useful information can be gained about the systemic vascular condition by examining the retinal blood vessels, and fundal examination should be a routine part of the assessment of all hypertensive patients.

The Diabetic Retinopathy Study (DRS)

- 1950's - Role of Photocoagulation controversial
- 1967 - Anecdotal reports of benefits
- 1968 - Airlie House Meeting
- 1971 - DRS Began
- 1976 - 1st Preliminary reports
- 1976 - 1987 14 Major Publications

Q - "Does Photocoagulation Surgery reduce the risk of severe visual loss in Diabetic Retinopathy?"
Studied natural history of Diabetic Retinopathy without photocoagulation and to compare Xenon & Argon.

Patients 1727 from 15 centres randomised to Indefinite Deferral, Xenon or Argon.
1976 the Indefinite Group were stopped

Treatment parameters: Xenon 200-400 Spots 4.5 degree size
Blue-Green Argon 800 - 1600 Spots 500 micron 0.1sec
Light Blanching of Retinal Pigment Epithelium.
New Vessels Elsewhere treated directly

Results

Severe Visual Loss 16.3% of untreated eyes
5.3% of Xenon
7.4% of Argon

ie Severe Visual Loss risk reduced by half.

Regression of New Vessels - 38% of treated eyes had increase in New Vessels Elsewhere compared to 63% untreated.

Risk Factors for Severe Visual Loss

1. Vitreous or Preretinal Hemorrhage
2. New Vessels
3. New Vessels at the Optic Disc or within in one disc diameter
4. Severe New Vessels.

High-risk characteristics = 3 of these.

Risks of Treatment

1. Loss of 2 - 4 Lines of visual acuity 23% Xenon, (field loss)
9.8% Argon
5.6% untreated

However 1 year later there was no Difference between groups.

Macular oedema increased risk of visual loss.

Risk of Progression to High-Risks Characteristics in 1 Year	Treated	Untreated
No PDR	8.8%	15%
Mild New Vessels Elsewhere without Vitreous or Preretinal haemorrhages	8.5%	19.4%
Moderate - Severe New Vessels Elsewhere without Vitreous or Preretinal haemorrhages	12.2%	24.5%
Mild New Vessels at the Optic Disc without Vitreous or Preretinal haemorrhages	21.9%	58.7%

Other Findings

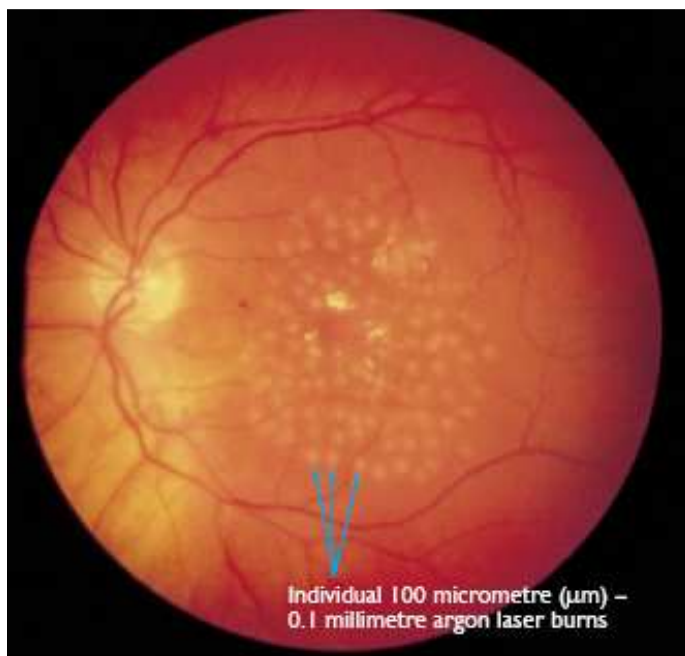
Adequate Treatment.

Eyes with treatment 1 Standard Deviation above mean (61% coverage of superonasal field) have HALF the risk of Severe visual loss compared to eyes treated 1 standard deviation below mean (27% coverage).

Treatment density and area both significant.

Prompt Full Scatter laser in eyes with high risk features reduces risk of severe visual loss by 50%

Severe NPDR & PDR with no high risk characteristics - No clear choice between treatment or Follow up waiting for high risk features. However in Non-Insulin Dependant Diabetic (NIDDM) the risk is much higher and Treatment is appropriate. ? pure local treatment to New Vessels Elsewhere.



The Early Treatment Diabetic Retinopathy Study (ETDRS)

Objectives

1. When in course of Diabetic Retinopathy is it most effective to do Laser?
2. Is Laser effective in? Diabetic maculopathy
3. Is Aspirin helpful?

Patients: Mild, Moderate or severe Nonproliferative diabetic Retinopathy or early proliferative diabetic retinopathy.

Groups 2707 pts

1. Moderate NPDR or Early PDR - Laser or deferred.
Laser - either
 - a. Immediate full Pan Retinal Argon Laser Photocoagulation to the Retina 1200 - 1600 0.1 sec 500 microns. 2 treatment sessions 2 weeks apart. No more than 900 burns in one session and no more than 5weeks to complete treatment.
 - b. Immediate mild scatter Pan Retinal Argon Laser Photocoagulation to the Retina. 400-650 burns spaced more than one burn width apart scattered uniformly. In one session.
2. Eyes with Macular edema & Less severe Retinopathy.
3. Eyes with macular edema & Severe Retinopathy

Definitions

Macular Edema Thickening of retina +/- hard exudates with in one disc diameter of fovea

CSME One or more of:

1. Retinal thickening within 500um of macular
2. Hard Exudates with in 500um if associated with retinal thickening
3. Zone of retinal thickening one disc are in size at least part ofwhich is within one disc diameter of fovea.

Nonproliferative Diabetic Retinopathy

Mild NPDR >one microaneurysm

Moderate NPDR Extensive Intraretinal hemorrhages +/- Microaneurysms, +/- Cotton-wool spots, venous beeding, Intra Retinal Microvascular Abnormalities (IRMA)

Severe NPDR Cotton-wool spots, venous beeding, Intra Retinal Microvascular Abnormalities all in 2 quadrants or 2 in at least 2 quadrants with intraretinal hemorrhages and microaneurysms in all quadrants or 4-2-1 rule any one of

1. Intraretinal hemorrhages in 4 quadrants
2. Venous beading in 2 quadrants
3. Severe Intra Retinal Microvascular Abnormalities (IRMA) in one.

Results

Early Laser in NPDR or Early PDR reduced development of High Risk Signs by
50% in Full Scatter Vs Deferred group
25% in Mild Scatter Vs Deferred Group

Macular Edema & Less Severe Retinopathy

Immediate Focal & Delayed Scatter initiated only when more severe Retinopathy developed. 50% reduction
Eyes treated with Pan Retinal Argon Laser Photocoagulation to the Retina then focal did worse.

Macular edema & Sever Retinopathy

Immediate Focal & Immediate mild Scatter

Visual Fields

Significant loss for Full Scatter compared to Deferred or Mild scatter.

Macular Edema

Focal or Grid treatment reduced incidence of Moderate visual loss by 50%
Visual prognosis was worse for those with worse vision at baselin.

Aspirin: No effect. Also no harmful effect if required to use.

Summary of ETDRS Findings.

1. Scatter Laser NOT recommended for NPDR or early PDR. Considered for eyes approaching high risk characteristics
2. Focal Laser CSME and mild-moderate NPDR, Severed NPDR & PDR
3. Type II diabetics more at risk of Progression.

Lessons from study

1. Severity of intraretinal lesions (microaneurysms/hemorrhage, soft exudates, cotton-wool spots, IRMA, venous beading, arteriolar abnormalities) is important in predicting progression and the frequency of follow-up visits.
2. New Vessels at the Optic Disc single most prognostic feature when >standard photo 10A (new vessels greater than or equal to one-third to one fourth disc area), panretinal photocoagulation is strongly indicated.
3. NVE without preretinal vitreous hemorrhage is a weaker indicator for panretinal photocoagulation, and careful observation is reasonable.
4. Initial vitreous hemorrhage or preretinal hemorrhage is usually small and does not preclude panretinal Photocoagulation. Patients should be encouraged to report symptoms promptly.
5. Supplemental panretinal Photocoagulation is often effective in causing regression of vessels that persist or recur after initial treatment. Supplemental treatment may be concentrated near NVE, applied throughout the fundus, or extended into the posterior pole.
6. A knowledge of the tendency for neovascularisation to proliferate and then to regress is important in

considering the need for additional panretinal Photocoagulation. The goal of panretinal Photocoagulation should be controlling neovascularisation rather than completely eliminating it.

7. In the presence of a complete posterior vitreous detachment, PDR rarely causes retinal traction.
8. Elevated neovascularisation is less affected by panretinal Photocoagulation than retinal surface neovascularisation.
9. Photocoagulation burn size is influenced not only by spot size but also by energy intensity. Therefore, the number of burns of a specified size is not an adequate measure of treatment applied.
10. Vascular narrowing frequently accompanies quiescence of the retinopathy.
11. Intense local Photocoagulation of NVE may produce noticeable scotomas and nerve-fiber layer defects.
12. Macular Photocoagulation improves the course of eyes with CSME, and prompt treatment is preferable to permanent non treatment. However, progression is slow, and treatment deferral with careful monitoring may be a useful strategy when thickening of the center of the macula is equivocal or when treatable lesions are close to the foveal center.
13. Macular edema should be treated prior to panretinal Photocoagulation or concurrently.
14. Hard exudates may increase when macular edema decreases and can threaten central vision.
15. ETDRS investigators emphasized careful follow up after initial treatment of CSME, with retreatment whenever CSME and treatable lesions were present.
16. Fluorescein leakage without retinal thickening does not constitute macular edema.

The Diabetes Control and Complications Trial

Insulin Dependant Diabetic

Tight control reduced incidence of Retinopathy 27%

76% reduction in 3 step progression

61% reduction of progression to severe Retinopathy

59% reduction in need for laser

Goal of American Diabetes Association is all Insulin Dependant Diabetic HbA1C <7%

The UKPDS Prospective Diabetes Study Trial.

Type II diabetics

HbA1C <7.1 & Blood Pressure <140/80 Latest aim.

Cholesterol also should be controlled some evidence helps resolve exudates.

is target that should be aimed for in all diabetic patients, but of course particularly important in those with Retinopathy. Thus in the Diabetic eye clinic it is important to know at least these two parameters. This is often not difficult where the general diabetic care is in the same hospitals with the same notes, but can be very difficult or impossible without repeating the tests if the diabetic care is undertaken by the GP or at another hospital. Other risk factors to consider are microalbuminuria, smoking and dyslipidaemia. However with such good evidence that the amount of Retinopathy is less in this group this has not become an important factor. This study set out to answer the question "Does tightly controlled blood pressure reduce the risk of complications in diabetes" The study clearly showed it did as was the diabetic control. BMJ 317 Sept 1998.

Useful Web sites

www.diabeticretinopathy.org.UK

www.eyetextbook.co.UK

www.doh.gov.uk/

New Developments

Pascal Laser

TAL[®] (Pattern Scan Laser) Photocoagulator is a fully integrated pattern scan laser system designed to treat retinal diseases using a single spot or a predetermined pattern array of up to 56 spots.

The PASCAL technology platform is based upon the use of a proprietary, semi-automated, pattern generation method employing short 532 nm laser pulses. These laser pulses are delivered in a rapid predetermined sequence resulting in improved precision, safety, patient comfort, and a significant reduction in treatment time compared with single-spot photocoagulation.

Pre-clinical animal studies, as well as initial pilot studies in humans indicate that in addition to reducing treatment duration for typical patients with proliferative diabetic retinopathy, the number of sessions may also be reduced.



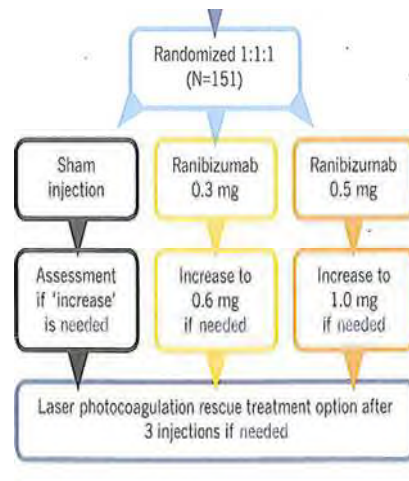
Anti-VEGF treatments for Diabetic eye disease.

Based on the successful trials of Lucentis in wet Macular degeneration, people have now tried this in Diabetes. Trials are currently under way and from these and my personal experience we are seeing significant benefit in two groups:

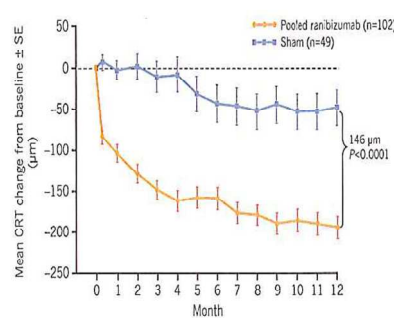
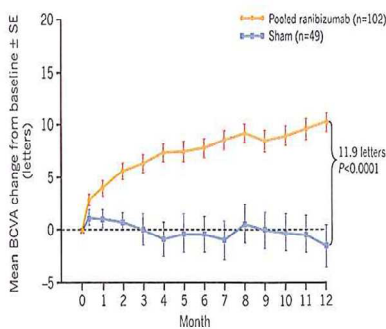
1. Severe proliferative disease including iris new vessels: These are closed very quickly with the Anti-VEGF either Avastin or Lucentis. Thus a hot eye with a lot of proliferative disease can be very quickly settled with an intra vitreal injection of one of these agents.
2. Diffuse macular odema that is not treatable by laser. Some patients have diffuse fluid at the macular that either does not respond to laser or is too close to the fovea to treat safely. These drugs also dry the fluid and improve the vision then allowing safer laser if need be. Increasing evidence of effectiveness using both Avastin and Lucentis. It is likely that Lucentis will get a licence for Diabetic macular odema next year 2011. The FDA has approved Lucentis for Vein Occlusions in 2010

Resolve Trial

- 1 Yr RCT Phase II, Europe, Australia, Asia
- >18 years old
- Type 1 or 2
- Focal or diffuse diabetic macular oedema
- Has to have Foveal oedema.



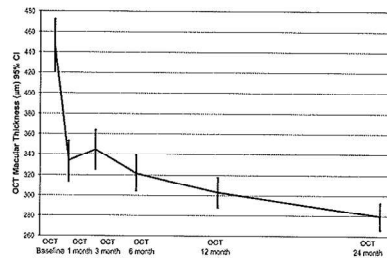
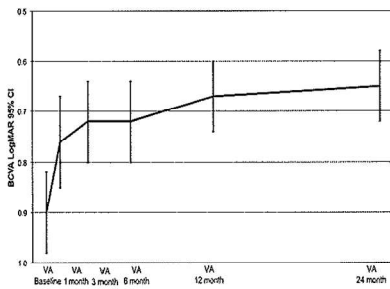
Summary results.



Avastin (Bevacizumab) for DIABETIC MACULAR OEDEMA

- Pan American Collaborative Retina Study group 24 month results
- Retrospective study, Intervetional study
- 115 Patients
- Injections average 5.8 (1 to 15)
- Vision improved 0.92 to 0.76 (0.16)
- OCT decreased from 466 to 286 microns

Results



NICE

Lucentis has been licensed for DME in January 2011. The trial data has been sent to NICE. They have unfortunately announced their initial assessment and despite a reasonable QUALY their recommendation is that the treatment is too expensive and not cost effective. It is not to be available in the NHS. This is only the preliminary document and further discussions/feedback may change this. This means that only Avastin is available in the NHS for DME. Avastin is less than 1/10 of the Price of Lucentis though and is sourced from Moorfields Pharmacy. An appeal has been lodged and will be heard on 4 October 2011.

We have been treating DME for the past 2 years and our data is consistent with the Published READ trial for diabetes which is 10 letters of improvement in vision over one year (ie 2 lines of vision). Treating DME

with Avastin or Lucentis is now routine in some eye units, but is likely to become more common once NICE publish their recommendations.

Newer slow release preparations are being developed specifically for diabetes and we can expect to see further development in this area over the next few years.

Mr. Nicholas Lee
Consultant Ophthalmologist at Hillingdon and The Western Eye Hospital
Diabetic Screening Service Lead Hillingdon & KCW
NHS email nicklee@leemeedical.co.uk

This document was created with Win2PDF available at <http://www.win2pdf.com>.
The unregistered version of Win2PDF is for evaluation or non-commercial use only.
This page will not be added after purchasing Win2PDF.